

ASCCP COLPOSCOPY STANDARDS

How do these apply to the management of our patients?

Stephanie Phillips, CRNP

OBJECTIVE

- Learn the fundamentals of risk-based guidelines for managing patients (ASCCP Colposcopy Standards)

BACKGROUND

- Published in 2017
- Purpose: To standardized colposcopy practice and increase the quality of colposcopy services delivered to patients in the United States by providing a core set of recommendations.

ASCCP COLPOSCOPY STANDARD #1

- The ASCCP Terminology of Colposcopic Practice
 - Provides standardized terminology for colposcopic practice and criteria for reporting of colposcopic findings
 - Goal: To simplify, clarify, and standardize reporting and documentation of colposcopic findings

COLPOSCOPY DOCUMENTATION

- Minimal reporting criteria
 - Fully/not fully visualized squamocolumnar junction
 - Presence or absence of acetowhitening
 - Presence or absence of lesion(s) – acetowhite or other
 - Colposcopic impression

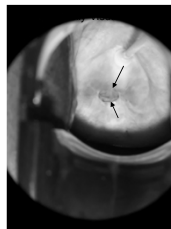
COLPOSCOPY DOCUMENTATION

- Comprehensive reporting criteria
 - Fully/not fully visualized cervix
 - Fully/not fully visualized squamocolumnar junction
 - Presence and location of acetowhitening
 - Presence and visualization of a lesion

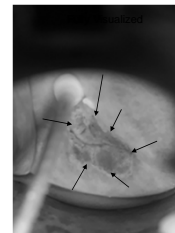
COLPOSCOPY DOCUMENTATION

- Color/contours/borders/vascular changes of a lesion
- The location and size(s) of lesions (s)
- If biopsies and/or endocervical curettage (ECC) performed
- Colposcopy impression

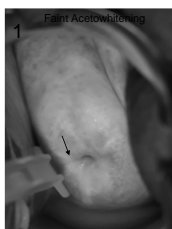
COLPOSCOPY DOCUMENTATION



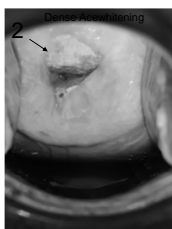
- Squamocolumnar Junction (SCJ)
- Area where the squamous epithelium and the columnar epithelium meet.
 - Identification is important because this is where dysplastic changes begin.
 - Failure to ID is most common error in colposcopy.



COLPOSCOPY DOCUMENTATION



- Acetowhitening (AWE)
1. Thin, faint, translucent with indistinct borders – low grade changes
 2. Dense, opaque with distinct borders – high grade changes



ASCCP COLPOSCOPY STANDARD #2

- Risk-Based Colposcopy Practice
 - Estimated from screening/triage test and colposcopic impression
 - Goal: To guide how many biopsies should be taken based on risk of cervical precancer to maximize detection of CIN2+ as patients are managed less aggressively

BIOPSY RECOMMENDATIONS

- Untargeted biopsies are not recommended for patients at the lowest end of risk.
- Lowest risk patients are defined as:
 - Cytology less than HSIL
 - No evidence of HPV 16 or 18
 - A completely normal colposcopic impression (no acetowhitening, metaplasia, or other visible abnormality and a fully visualized squamocolumnar junction)

BIOPSY RECOMMENDATIONS

- For those NOT meeting the lowest risk criteria:
 - Multiple biopsies targeting all areas of acetowhite, metaplasia, or higher abnormalities are recommended.
 - At least 2 and up to 4 biopsies are recommended targeting all areas of AWE.

BIOPSY RECOMMENDATIONS

- In nonpregnant patients 25 years or older with a very high risk of precancer, either immediate excisional procedure or multiple targeted biopsies is acceptable.

BIOPSY RECOMMENDATIONS

- Endocervical Curettage (ECC) is indicated for nonpregnant patients:
 - When SCJ is not fully visualized
 - When a lesion is present
 - When no lesion is present in those NOT at lowest risk (ex. NIL/HPV pos x 2)

ASCCP COLPOSCOPY STANDARD #3

- Colposcopy procedures for minimally acceptable practice
 - Precolposcopy Evaluation
 - Examination
 - Documentation
 - Biopsy Sampling
 - Postcolposcopy Procedures

WHY ARE THE COLPOSCOPY STANDARDS IMPORTANT TO ME WHEN I DO NOT DO COLPOSCOPIES?

1. Application of the new guidelines is based on colposcopy practice that follows the ASCCP Colposcopy Standards
2. To ensure our patients are managed appropriately following the best evidence based practice recommendations

WHY IS THIS IMPORTANT TO OUR PATIENTS?

- May impact future or current management.
- Can alter management and lead to suboptimal outcomes.
- May result in over or under treatment of abnormal findings.

HOW DO WE USE THESE STANDARDS WITH APPLICATION OF THE NEW GUIDELINES?

OUR PATIENT

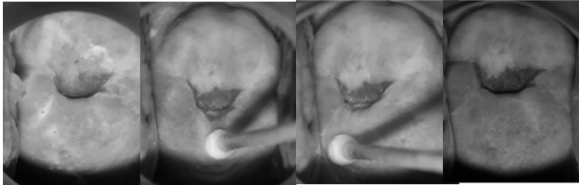
25 yo
 G2P1
 Pap: HSIL
 Seeking pregnancy
 Referred for colposcopy

COLPOSCOPY NOTE

25 yo, G2P1, presents for colposcopy due to HSIL pap of 1/2020. SCJ fully visualized with faint AWE noted at 11-12 o'clock. ECC and cervical biopsies at 12 o'clock obtained. Hemostasis attained with Monsels solution. Impression: high grade. Instructions given re: pelvic rest for 2 weeks and follow up in 7 to 10 days for results.

COLPOSCOPY IMAGES

| | | | |
|-------------------------|-------------------------|------------------------|-----------------|
| 1. Prior to Acetic Acid | 2. SCJ Fully Visualized | 3. AWE @ 11-12 o'clock | 4. Green Filter |
|-------------------------|-------------------------|------------------------|-----------------|



PATHOLOGY RESULTS

- Cervical Bx – Mod dysplasia (CIN 2, HSIL)
- ECC – Fragments of benign endocervical glands, no dysplasia identified
- Plan: LEEP

IS THIS AN APPROPRIATE PLAN??

CIN2 in Patients Concerned with Effects on Future Pregnancy

Summary:

- 25 yo
- Desires pregnancy
- Pap: HSIL
- SCJ fully visualized
- Bx: CIN 2
- ECC: benign
- Plan: LEEP

FIGURE 6. This figure describes management of CIN 2 in patients whose concerns about the effects of treatment on a future pregnancy outweigh their concerns about cancer. Also addressed is the management of histologic CIN2 not further specified in women younger than 25 years, for whom observation is acceptable, and for women 25 years or older for whom treatment is preferred.

POSTCOLPOSCOPY COUNSELING

Phone call to pt to discuss results/plan of care. Results of mod dysplasia - CIN2 on cervical Bx given to pt. Management options (LEEP vs observation at 6 m with colpo/cotest) due to age of 25 and plans for future pregnancy were discussed w/pt. Counseled CIN 2 is precursor to cervical CA with LEEP being treatment choice to remove the ABN cells on cervix, informed that LEEP could increase risk of preterm labor with future pregnancies. Discussed w/pt conservative management of repeat colpo and cotest in 6 m, stressing importance of FU to evaluate for progression of disease.

POSTCOLPOSCOPY COUNSELING

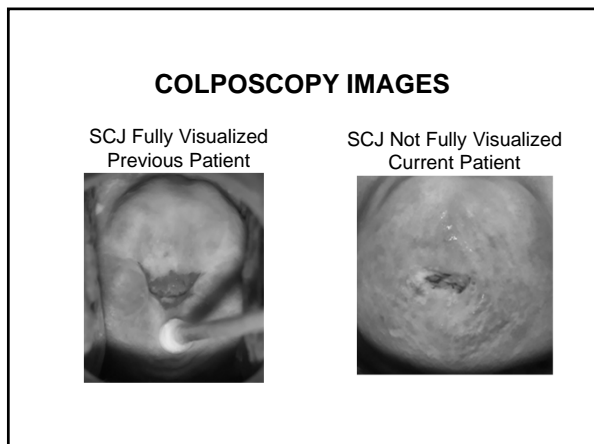
Pt decided to proceed with conservative management/surveillance. Instructed to notify health department of any changes in phone number or address to ensure contact can be made to schedule 6 m FU as discussed. All questions were answered and patient verbalized understanding of plan for colpo and cotest in 6 m.

OUR PATIENT

30 yo
G2P2
Pap: HSIL
BTL
Referred for colposcopy

COLPOSCOPY NOTE

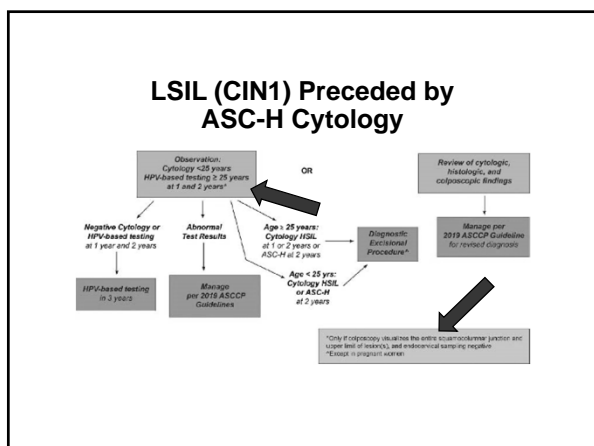
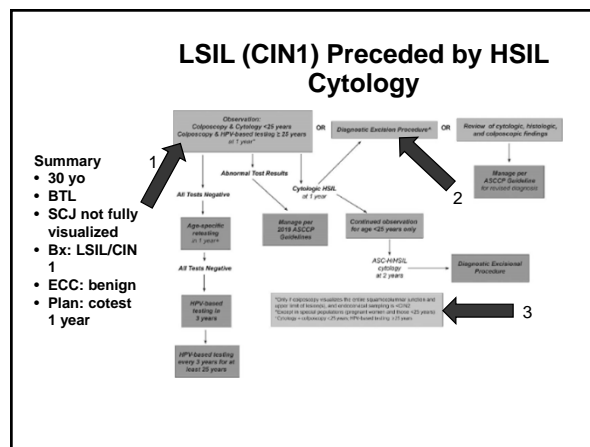
30 yo, G2P2, presents for colposcopy due to HSIL 11/2019. External genitalia unremarkable. SCJ not fully visualized. Faint AWE from 9 o'clock. ECC and cervical biopsies at 9 o'clock obtained. Hemostasis attained with Monsels solution. Impression: low grade. Instructions given re: pelvic rest for 2 weeks and follow up in 7 to 10 days for results.



PATHOLOGY RESULTS

- Cervical Bx – Mild dysplasia (LSIL, CIN 1)
- ECC – Fragments of benign endocervical glands, no dysplasia identified
- Outside provider plan: Cotest in 1 year

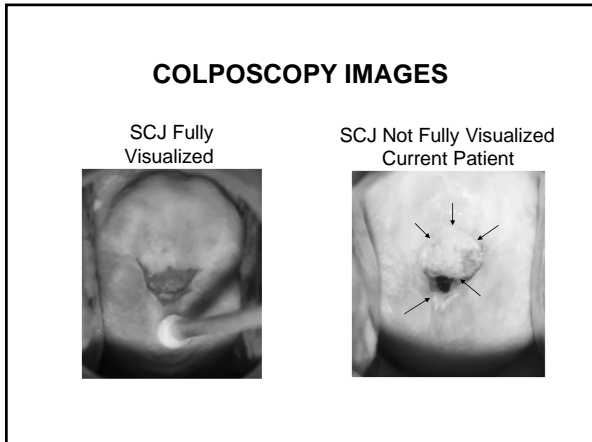
IS THIS AN APPROPRIATE PLAN??



35 yo
G3P3
Pap: HSIL
BTL
Referred for colposcopy

COLPOSCOPY NOTE

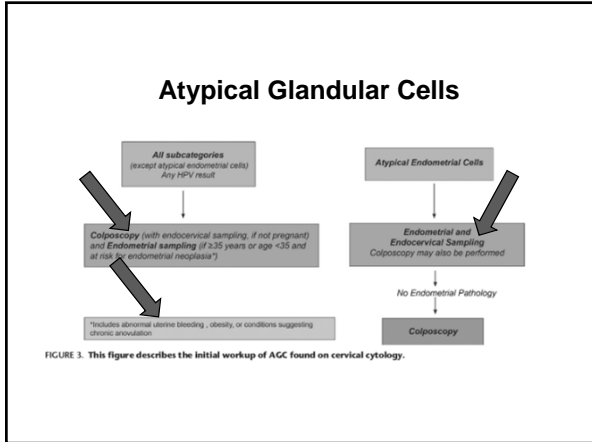

33 yo, G3P3, presents for colposcopy due to HSIL 11/2019. External genitalia unremarkable. SCJ not fully visualized. Dense AWE from 9-3 and 6 o'clock. ECC and cervical biopsies at 9 and 6 o'clock obtained. Hemostasis attained with Monsels solution. Impression: high grade. Instructions given re: pelvic rest for 2 weeks and follow up in 7 to 10 days for results.

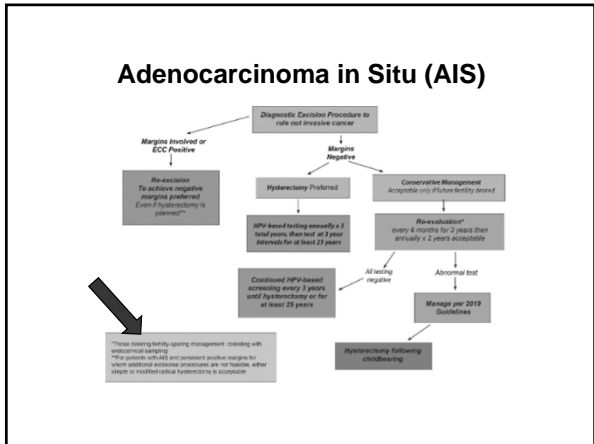


PATHOLOGY RESULTS

- Cervical Bx – Severe dysplasia (HSIL, CIN 3)
- ECC – CIN 3
- Outside provider plan: Cryotherapy

IS THIS AN APPROPRIATE PLAN??





CONSULTS

IF AT ANY POINT A MANAGEMENT PLAN IS RECEIVED THAT DOES NOT ALIGN WITH THESE GUIDELINES, A CONSULT IS ALWAYS NEEDED.

CONCLUSION

Our responsibility goes much further than “refer for colpo”.