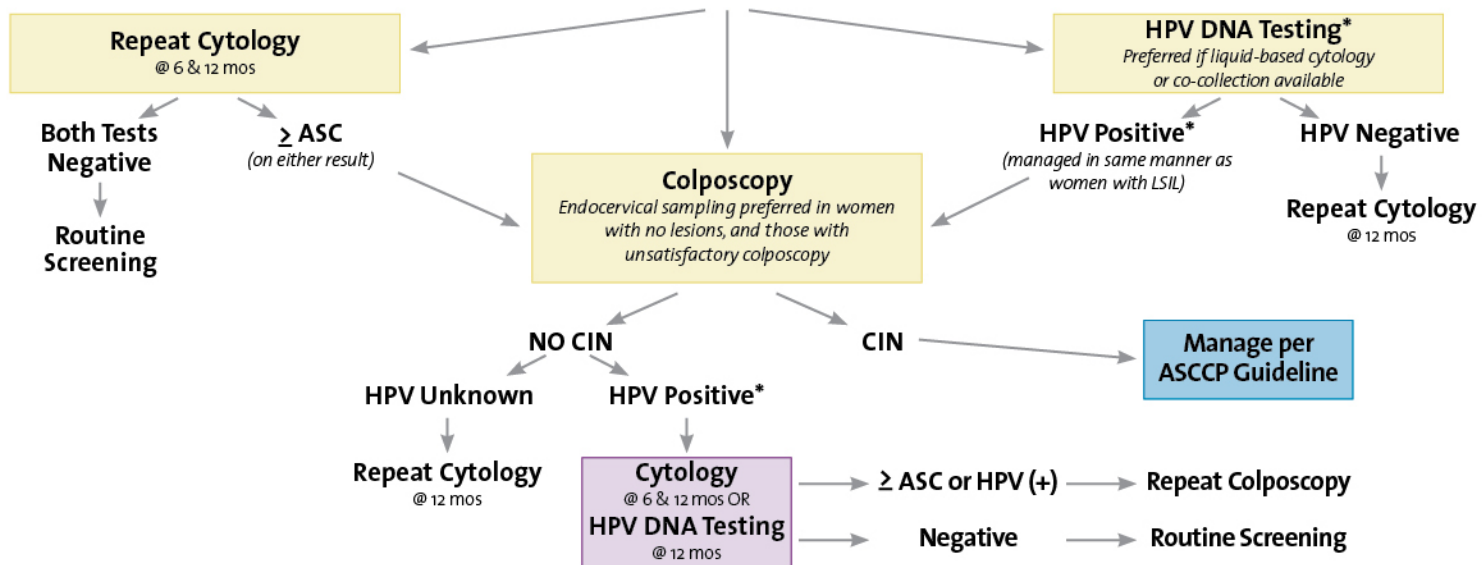
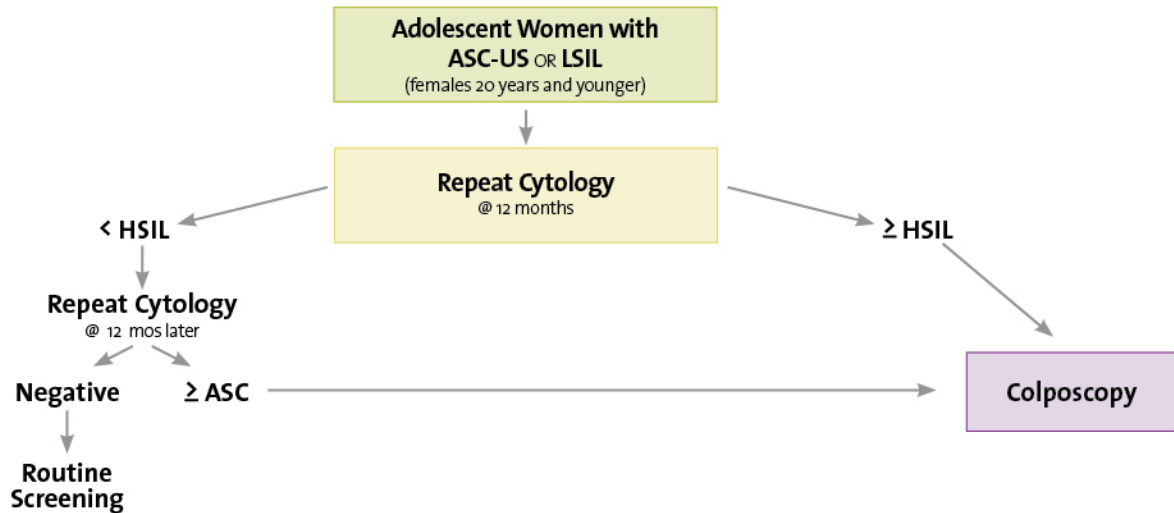


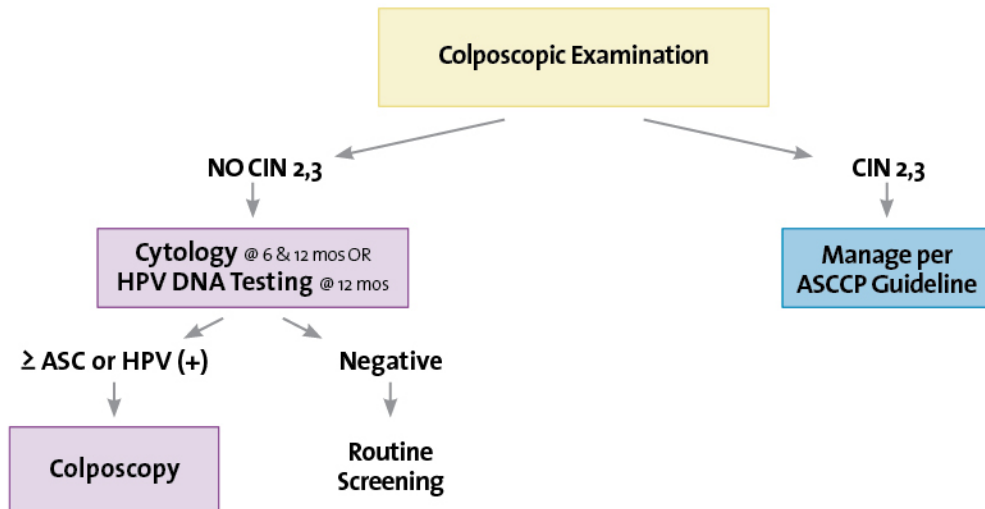
# Management of Women with Atypical Squamous Cells of Undetermined Significance (ASC-US)



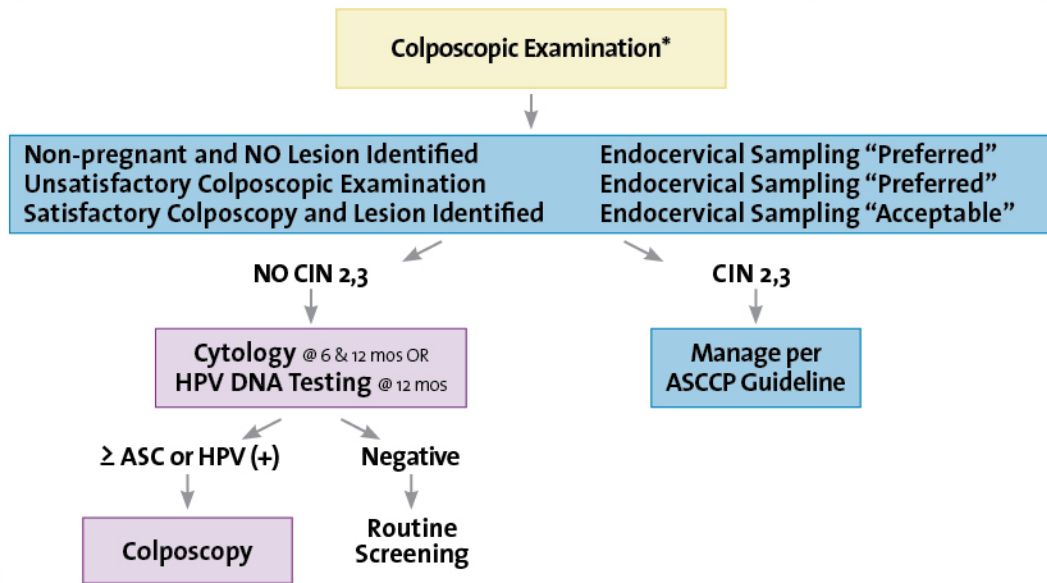
## Management of Adolescent Women with Either Atypical Squamous Cells of Undetermined Significance (ASC-US) or Low-grade Squamous Intraepithelial Lesion (LSIL)



## Management of Women with Atypical Squamous Cells: Cannot Exclude High-grade SIL (ASC - H)

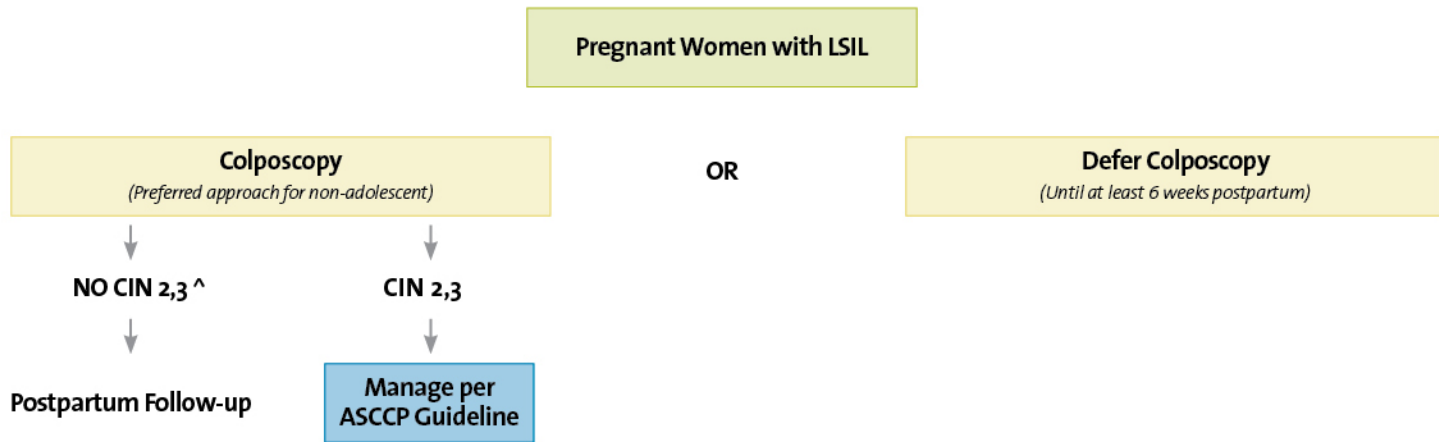


## Management of Women with Low-grade Squamous Intraepithelial Lesion (LSIL) \*

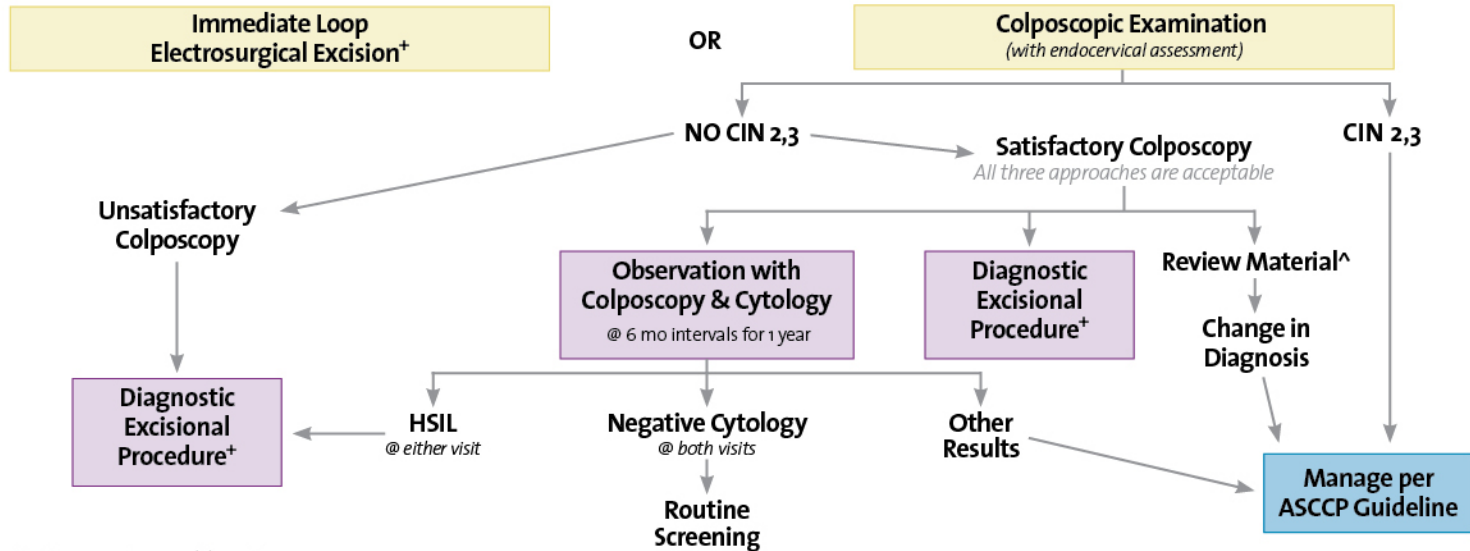


\*Management options may vary if the woman is pregnant, postmenopausal, or an adolescent - (see text)

# Management of Pregnant Women with Low-grade Squamous Intraepithelial Lesion (LSIL)



# Management of Women with High-grade Squamous Intraepithelial Lesion (HSIL) \*

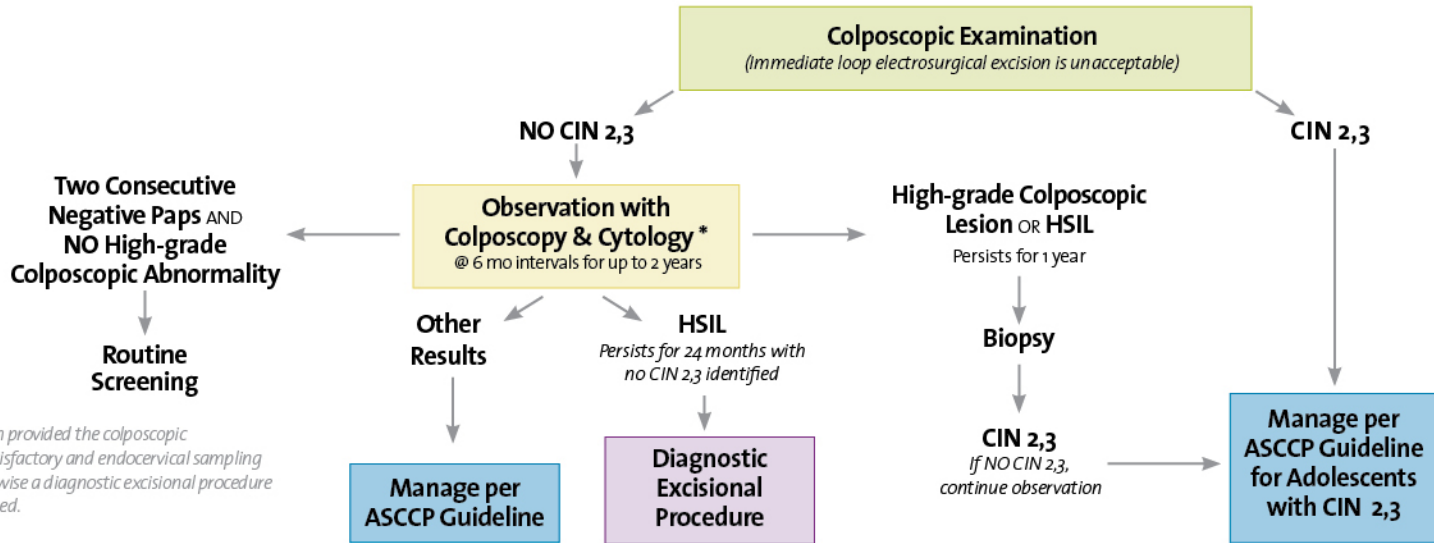


+ Not if patient is pregnant or an adolescent

^ Includes referral cytology, colposcopic findings, and all biopsies

\* Management options may vary if the woman is pregnant, postmenopausal, or an adolescent

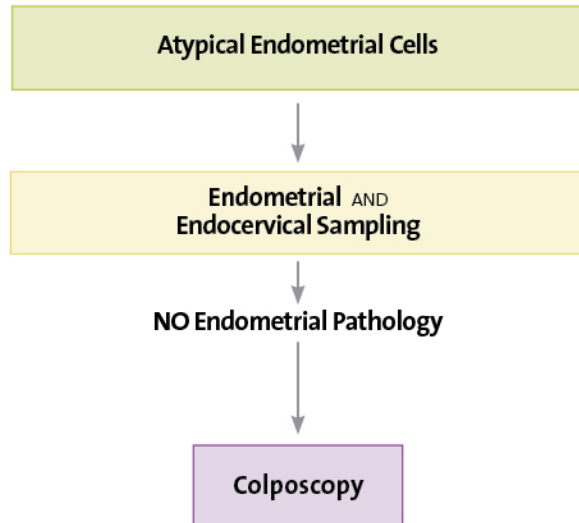
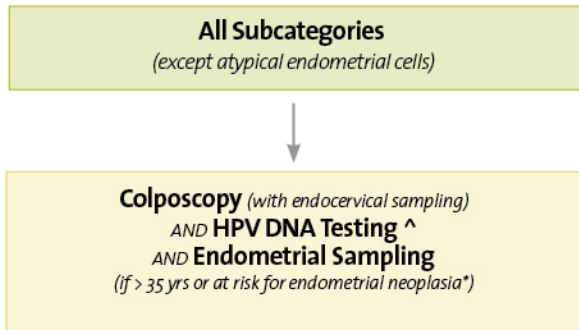
# Management of Adolescent Women (20 Years and Younger) with High-grade Squamous Intraepithelial Lesion (HSIL)



\* Preferred approach provided the colposcopic examination is satisfactory and endocervical sampling is negative. Otherwise a diagnostic excisional procedure should be performed.



## Initial Workup of Women with Atypical Glandular Cells (AGC)

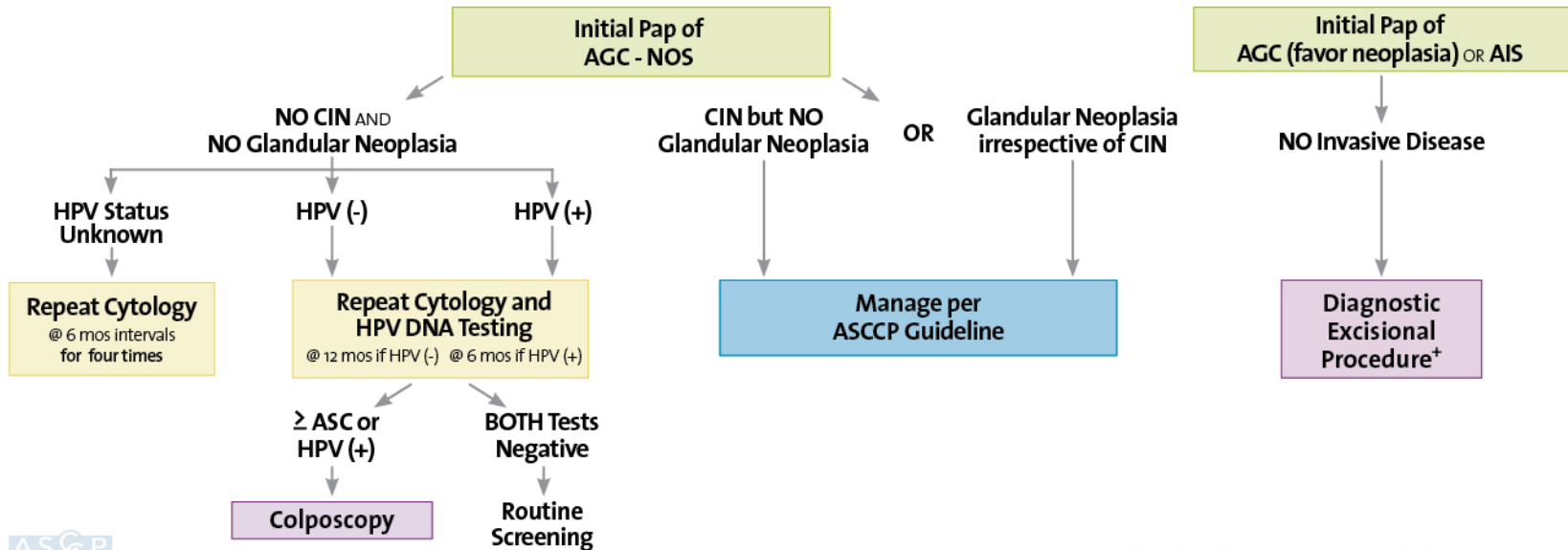


^ If not already obtained. Test only for high-risk (oncogenic) types.

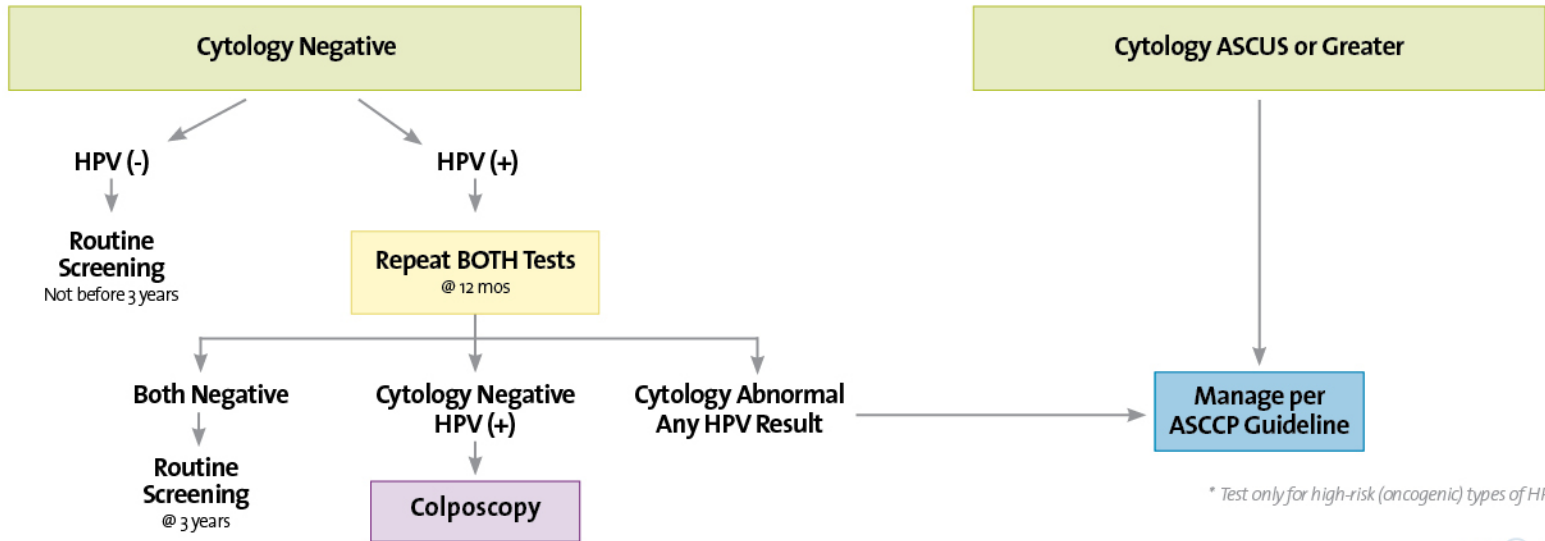
\* Includes unexplained vaginal bleeding or conditions suggesting chronic anovulation.



## Subsequent Management of Women with Atypical Glandular Cells (AGC)



## Use of HPV DNA Testing \* as an Adjunct to Cytology for Cervical Cancer Screening in Women 30 Years and Older



\* Test only for high-risk (oncogenic) types of HPV